Science of the Total Environment 605–606 (2017) 139–146

Contents lists available at ScienceDirect

Science of the Total Environment

journal homepage: www.elsevier.com/locate/scitotenv

Oral mycoses in avian scavengers exposed to antibiotics from livestock farming

Aida Pitarch [a], Concha Gil [a], Guillermo Blanco [b,*]

[a] Department of Microbiology II, Faculty of Pharmacy, Complutense University of Madrid (UCM) and Ramón y Cajal Institute of Health Research (IRYCIS), Plaza Ramón y Cajal s/n, 28040 Madrid, Spain
[b] Department of Evolutionary Ecology, Museo Nacional de Ciencias Naturales (CSIC), José Gutiérrez Abascal 2, 28006 Madrid, Spain

HIGHLIGHTS

- Fungal infections pose a major threat to animals worldwide.
- Thrush-like lesions were recorded in four avian scavenger species exposed to antibiotics.
- 14 yeast species were isolated from the oral lesions in this unprecedented outbreak.
- These finding are alarming due to the delicate conservation status of the affected hosts.

GRAPHICAL ABSTRACT



ARTICLE INFO

Article history:
Received 25 April 2017
Received in revised form 4 June 2017
Accepted 18 June 2017
Available online 27 June 2017

Editor: D. Barcelo

Keywords:
Antimicrobials
Livestock
Candidiasis
Scavengers
Yeast species

ABSTRACT

The exposure to antimicrobial pharmaceuticals as environmental contaminants can exert direct and indirect detrimental effects on health of wildlife. Fungal infections pose a major threat to domestic, captive-housed wild and free-ranging wild animals worldwide. However, little is known about their role in disease in birds in the wild. Here, we evaluated the incidence of thrush-like lesions in the oral cavity of wild nestling cinereous vultures (*Aegypius monachus*), griffon vultures (*Gyps fulvus*), Egyptian vultures (*Neophron percnopterus*) and golden eagles (*Aquila chrysaetos*) exposed to veterinary antibiotics via the consumption of medicated livestock carcasses. Lesions, which varied in number, size and location, were more frequent in the cinereous (77.8%, $n = 9$) and griffon vultures (66.7%, $n = 48$) than in the Egyptian vultures (28.6%, $n = 21$) and golden eagles (28.6%, $n = 7$). In all individuals (100%, $n = 24$) of a subsample of the affected nestlings, yeast species were isolated from thrush-like oral lesions and identified using a well-established system based on their carbohydrate assimilation profiles and other complementary tests. Fourteen yeast species from seven genera (*Candida*, *Meyerozyma*, *Pichia*, *Yarrowia*, *Cryptococcus*, *Rhodotorula* and *Trichosporon*) were isolated from the lesions of the four host species. We found differential infections and effects depending on host age-related exposure or susceptibility to different yeast species across the development of nestling griffon vultures. This unprecedented outbreak of oral mycoses is alarming because of the delicate conservation status of several of the affected species. The role of livestock antibiotics in the transition of yeast species from commensal to opportunistic pathogens should be evaluated in an attempt to avoid the detrimental effects of contamination and disease on host health, as well as on the transmission of fungal emerging pathogens among wildlife populations and species, and their dissemination across livestock and human populations.

© 2017 Elsevier B.V. All rights reserved.

* Corresponding author.
E-mail address: gblanco@mncn.csic.es (G. Blanco).

http://dx.doi.org/10.1016/j.scitotenv.2017.06.144
0048-9697/© 2017 Elsevier B.V. All rights reserved.

1. Introduction

Fungal infections have recently caused alarming population declines in several wild animals and plants worldwide (Fisher et al., 2012). Diverse yeast-like fungal species, such as some *Candida* spp., are common commensal members of the normal microbiome in the oral cavity and gastrointestinal tract of humans, livestock and wild animals (Velasco, 2000; Cabañes, 2010; Farah et al., 2010; Mukherjee et al., 2015; Neville et al., 2015). However, these and other opportunistic fungi can cause infection when an imbalance is produced in their ecologic niches. This can occur from an impairment of the host's immune system, disruption of the host's natural barriers, or alterations in the host's normal microbiota composition due, for example, to the prolonged use of broad-spectrum antibacterial therapy (Lin et al., 2005; Pitarch et al., 2006; Hebecker et al., 2014). The exposure to antimicrobial pharmaceuticals as environmental contaminants can exert direct detrimental effects on wildlife (Arnold et al., 2014). Indirect effects on health by promoting the alteration of the normal and protective microbiota are also likely but they have been much less investigated.

In birds, opportunistic fungal infections (in particular, candidiasis) have mostly been reported in stressed, immunocompromised and medicated poultry and pets (Mancianti et al., 2002; Vieira and Acqua-Coutinho, 2009; Wu et al., 2012). Their main clinical manifestations include circular and ulcerative milky nodules and plaque-like areas that often form clusters in the upper areas of the digestive tract (Friend and Franson, 1999; Velasco, 2000; Deem, 2003), resembling oral thrush in humans (Farah et al., 2010; Lalla et al., 2013). Other clinical manifestations of these mycoses in poultry and pet birds comprise dysphagia, regurgitation, vomiting, retarded growth, ruffled feathers, depression, emaciation and anorexia (Friend and Franson, 1999; Velasco, 2000; Deem, 2003). In apparently healthy wild individuals, multiple yeast species have been isolated from normal or transient gastrointestinal microbiota (Cafarchia et al., 2006; Brilhante et al., 2012). Oral mycoses have also been described in wild birds that are temporally or permanently housed in captivity and have several predisposing factors, including underlying immunosuppressive or debilitating diseases, prolonged therapy with broad-spectrum antibiotics, malnutrition, unsanitary conditions, and captivity-related stresses (Velasco, 2000; Deem, 2003; Caliendo and Bull, 2011; Brilhante et al., 2012). However, fungal infections have rarely been found causing clinical lesions in free-range wild birds (Friend and Franson, 1999; Redig, 2003).

Because yeasts are cosmopolitan and ubiquitous saprophytes, environments contaminated with refuse, wastewater from urban effluents, and litter and excreta from livestock operations could favor their proliferation and dissemination (Friend and Franson, 1999; Feng et al., 2010; Meissner et al., 2015). These unsanitary conditions, including the accumulation of decomposing carcasses and the fecal material of several livestock species, putrid water, and the spread of unwanted organisms like rats, often concur in feeding stations used as management and conservation tools for vultures and other avian scavengers worldwide (Cortés-Avizanda et al., 2016). In particular, European vultures have increased their dependence on livestock carcasses from these feeding stations and farm surroundings over carcasses of free-ranging livestock (Cortés-Avizanda et al., 2016). These carcasses could pose health risks to avian scavengers due to ingestion of veterinary pharmaceuticals (Blanco et al., 2016, 2017a, 2017b), exposure to parasites (Blanco et al., 2017c) and microbial pathogens that may have developed multi-resistance mechanisms to these drugs (Blanco, 2015). This is mainly because carrion used for this purpose is generally from livestock from factory farming (such as poultry and swine) that are often sick, medicated just before death, and disposed of in feeding stations a short time afterwards without a withdrawal period or residue control (Blanco et al., 2016, 2017a; Cortés-Avizanda et al., 2016).

The ingestion of veterinary drugs present in carcasses of medicated livestock may have direct effects on the health of avian scavengers with eventual catastrophic consequences on their populations, as occurred in the diclofenac crisis in Asia (Prakash et al., 2012). The antimicrobial agents frequently used in livestock farming may potentially have direct negative effects on scavenger's health when an acute exposure occurs from intensively medicated livestock carcasses, but also indirect negative effects. They can depress the ability of the immune system to fight against infection (Walker, 2000; Keeney et al., 2014), alter the host microbiota composition and cause other imbalances that lead to gut dysbiosis and colonization and proliferation of opportunist pathogens (Levy, 2000; Keeney et al., 2014). Antibiotic misuse or overuse can be directly implied in the overgrowth of opportunist fungi, especially *Candida* species (Cunha, 2001; Caliendo and Bull, 2011), able to cause superficial or even invasive mycoses by eliminating or disturbing competing bacteria of the host microbiome (Lin et al., 2005; Pfaller and Diekema, 2007; MacCallum, 2010).

The occurrence of disease, represented by gross lesions compatible with *Candida*-caused fungal infections, has been recorded in the oral cavity of nestling and adult wild vultures exposed to livestock antibiotics in central Spain (López-Rull et al., 2015; Blanco et al., 2017a). These lesions appear as milky, prominent and strongly attached nodules of variable size with a circular-to-elliptic form that often extends to larger and ulcerated plaque-like areas. The prevalence and the number of *Candida*-like yeast lesions are higher in nestlings than in adult vultures, and individuals with more lesions show a weaker hemagglutination reaction than those with a lower intensity infection (López-Rull et al., 2015). Microscopic observation of samples collected from these lesions revealed the presence of abundant yeast-like fungi as the potential etiological agents, but failed to record parasites such as *Trichomonas* sp. or helminths (Blanco et al., 2017a), which can cause similar lesions in the oral cavity of birds (Friend and Franson, 1999; Carter et al., 2008). Despite the widespread array of yeast species that may cause pathogenic effects in avian scavengers exposed to fluoroquinolones and other drugs, no study has yet identified the species involved in the mycoses recorded thus far.

In this work, we evaluated the prevalence, number and location of lesions present in the oral cavity of nestling cinereous vultures (*Aegypius monachus*), griffon vultures (*Gyps fulvus*) and Egyptian vultures (*Neophron percnopterus*), three obligate avian scavengers exposed to antibiotics through livestock carcasses in central Spain (Blanco et al., 2016, 2017a). We also examined nestling golden eagles (*Aquila chrysaetos*), a top predator and facultative scavenger raptor exposed to these drugs (Blanco et al., 2017b). For a subgroup of nestling cinereous and griffon vultures, we further conducted a selective cultivation and characterization of yeast-like fungi isolated from oral lesions to identify the species involved in infection. This information was complemented with the identification of yeast species from the lesions recorded in single nestlings of the other two obligate and facultative scavenger species. In addition, we assessed potential associations between the occurrence of particular yeast species in the oral lesions and host features, including age, sex and stressful conditions during growth in the griffon vulture, for which we could obtain a larger number of samples from nestlings with lesions.

2. Materials and methods

2.1. Study area, study species and fieldwork

Regular and intensive nest monitoring of the populations of obligate and facultative avian scavengers was conducted throughout the breeding season of 2013 and 2014 in the Central Mountains and associated canyons of the Castilian Highlands in central Spain (see details of the study area in Fargallo et al., 1998; Blanco, 2014). This area have one of the highest concentrations of farms devoted to fattening pigs reared under intensive conditions in Spain (Blanco, 2014).

The study species are listed in different categories of conservation, ranging from 'Least Concern' in the case of the griffon vulture and golden eagle, 'Near Threatened' in the cinereous vulture, and globally

'Endangered' in the Egyptian vulture due to severe declines experienced throughout its range (BirdLife International, 2016). Nests were regularly checked by telescope to verify breeding failure or success of each pair in fledging young following standard methodology as part of long-term monitoring of their populations (Martínez et al., 1997; Donázar et al., 2002; Sanz-Aguilar et al., 2017). When nestlings were 40–80 days old, depending on the species, their nests were accessed by climbing. Nestlings were banded, measured for wing and tail feather length to the nearest 1 mm with rules as a surrogate of age, and weighed to the nearest 1 g with balances. The number of fault bars in the primary tail feathers was recorded as a proxy of stressful conditions potentially impairing growth and development in nestlings (López-Rull et al., 2015). A drop of blood was used for sexing the individuals through molecular procedures (Wink et al., 1998).

The presence of lesions compatible with fungal infection in the oral cavity was examined in a sample of nestling cinereous vultures ($n = 9$ nestlings from different nests, one nestling per nest; 2013: 5 nestlings, and 2014: 4 nestlings), griffon vultures ($n = 48$ nestlings from different nests, one nestling per nest; 2013: 35 nestlings, and 2014: 13 nestlings), Egyptian vultures ($n = 21$ nestlings from 13 nests; 2013: 5 nests with one nestling and 3 nests with two nestlings, and 2014: 5 nests with two nestlings) and golden eagles ($n = 7$ nestlings from 6 nests; 2013: 3 nests with one nestling, and 2014: 2 nests with one nestling and 1 nest with two nestlings). The number of lesions was recorded according to their location in the oral cavity, and categorized as present on the tongue, pharynx or other locations (including palate and wall of the oral cavity). The presence of lesions was also evaluated in a sample of fledgling griffon ($n = 5$) and cinereous vultures ($n = 3$) found dehydrated and unable to fly several weeks after leaving the nests in the study area.

2.2. Sample collection of oral lesions

The material and mucosa forming the lesions was collected on a subset of the individuals examined in 2013–2014 (see above). Overall, we collected material from the oral lesions of nestling griffon ($n = 16$) and cinereous ($n = 6$) vultures. In addition, lesions from one nestling Egyptian vulture ($n = 1$) and golden eagle ($n = 1$) from the same area were also sampled to determinate the potential presence of yeast-like fungi causing disease in these species. The lesions were sampled by gently scraping their surfaces with sterile microbiological swabs that were subsequently inserted into tubes containing Amies transport medium (M40 transystem; VWR International Eurolab, Barcelona, Spain). Samples were kept at 4 °C and transported to the laboratory within 12 h after collection and processed within 1–2 h following their arrival at the laboratory.

2.3. Yeast isolation and identification

Samples from the oral lesions were used to inoculate and streak Sabouraud dextrose agar plates supplemented with 0.5 g/L chloramphenicol (Laboratorios Conda, Madrid, Spain) for the selective cultivation of fungi. Plates were incubated for 48 to 72 h, and growth of non-yeast-like and yeast-like fungal colonies in each plate was recorded. Discrete single yeast colonies with different macroscopic features were selected from the plates and then subcultured in chloramphenicol-supplemented Sabouraud dextrose agar plates for 48 h until pure cultures were obtained. A small portion of each isolate was placed in a drop of water held between a microscope slide and a cover slip (wet mount), and then observed under a phase-contrast microscope using a 40× objective (in its natural state, i.e. without previously being killed, fixed and stained) in order to confirm its yeast-like morphology (see also Supplementary material).

All yeast isolates from each oral sample were characterized by their carbohydrate assimilation profiles using the API 20 C AUX system (bioMérieux, Marcy l'Etoile, Francia) according to the manufacturer's instructions. This is an accurate well-established method for identification of yeast isolates to the species level (Ramani et al., 1998). Identification was achieved by comparing a 7-digit numerical profile based on the assimilation reaction profile and morphology test of each yeast isolate with the profiles of all taxa in the databases using the apiweb identification software (version 4.0; apiweb.biomerieux.com). The identification was considered complete if the profile was listed as excellent, very good or good and no further tests were suggested by the manufacturer. When one numerical profile was assigned to two or more possible yeast species, final identification was obtained using supplementary tests (morphology, resistance to cycloheximide, glucose acidification, vitamin requirement, nitrate assimilation, and esculin hydrolysis; see Supplementary material) as recommended by the manufacturer. Classification and nomenclature for all identified yeast species were further verified using UniProt (www.uniprot.org/taxonomy) and NCBI (www.ncbi.nlm.nih.gov/taxonomy) taxonomy databases.

3. Results

3.1. Prevalence, number and location of lesions

We recorded gross lesions compatible with yeast-like fungal infection in the oral cavity of nestlings of the three vulture species (Fig. 1) and golden eagles. The proportion of individuals with lesions differed among species (Fisher's exact test with Freeman-Halton extension, $P = 0.005$), this being higher in nestling cinereous and griffon vultures (>65% nestlings) than in Egyptian vultures and golden eagles (<30% nestlings; Fig. 2A).

The number of lesions per affected individual did not differ significantly among the host species (Kruskal-Wallis test, $\chi^2 = 0.32$, df = 3, $P = 0.96$; cinereous vulture: median = 2, range, 1–5, $n = 7$; griffon vulture: median = 2, range = 1–9, $n = 32$; Egyptian vulture: median = 2, range = 1–3, $n = 6$; golden eagle: median = 3.5, range = 1–6, $n = 2$). Out of the 47 individuals with oral lesions (pooling the four sampled host species), 40 (85.1%) showed lesions in a single location among the considered areas within the oral cavity, while 6 (12.8%) displayed lesions in two different locations, and one (a single griffon vulture, 2.1%) had lesions around its entire oral cavity (including tongue, pharynx and other locations). Most of the lesions were located on the tongue in the four host species. Lesions were also less frequently located in the palate and walls of the oral cavity (categorized as other parts) from the four host species, and in the pharynx from the cinereous and griffon vultures (Fig. 2B).

All fledgling griffon ($n = 5$) and cinereous vultures ($n = 3$) found dehydrated and unable to fly several weeks after leaving the nests in the study area showed the same kind of lesions in the oral cavity.

3.2. Isolated yeast species from the oral lesions

Yeast was isolated from the lesions of all cinereous ($n = 6$) and griffon vultures ($n = 16$) sampled (prevalence = 100%, Table 1). A total of 41 yeast isolates belonging to 2 phyla, 7 genera and 14 species within the kingdom *Fungi* were identified in the oral lesions from the four raptor species (Table 1). In particular, 10 and 28 different yeast isolates were characterized in the oral lesions in the nestling cinereous and griffon vultures (note that several yeast species were isolated from lesions of particular individuals). Seven and 12 yeast species (of 5 and 6 yeast genera) were isolated from oral lesions of the nestling cinereous and griffon vultures, respectively.

About half of the identified yeast species (6 out of the 14 species) belonged to the *Candida* genus, while the remaining isolated yeast species corresponded either to the *Rhodotorula* genus (3 species) or to the *Meyerozyma*, *Pichia*, *Yarrowia*, *Cryptococcus*, or *Trichosporon* genera (1 species each). Only one yeast species was isolated exclusively in the nestling cinereous vultures (*Trichosporon inkin*), while most of the identified yeast species (12 out of the 14 species) were isolated in the

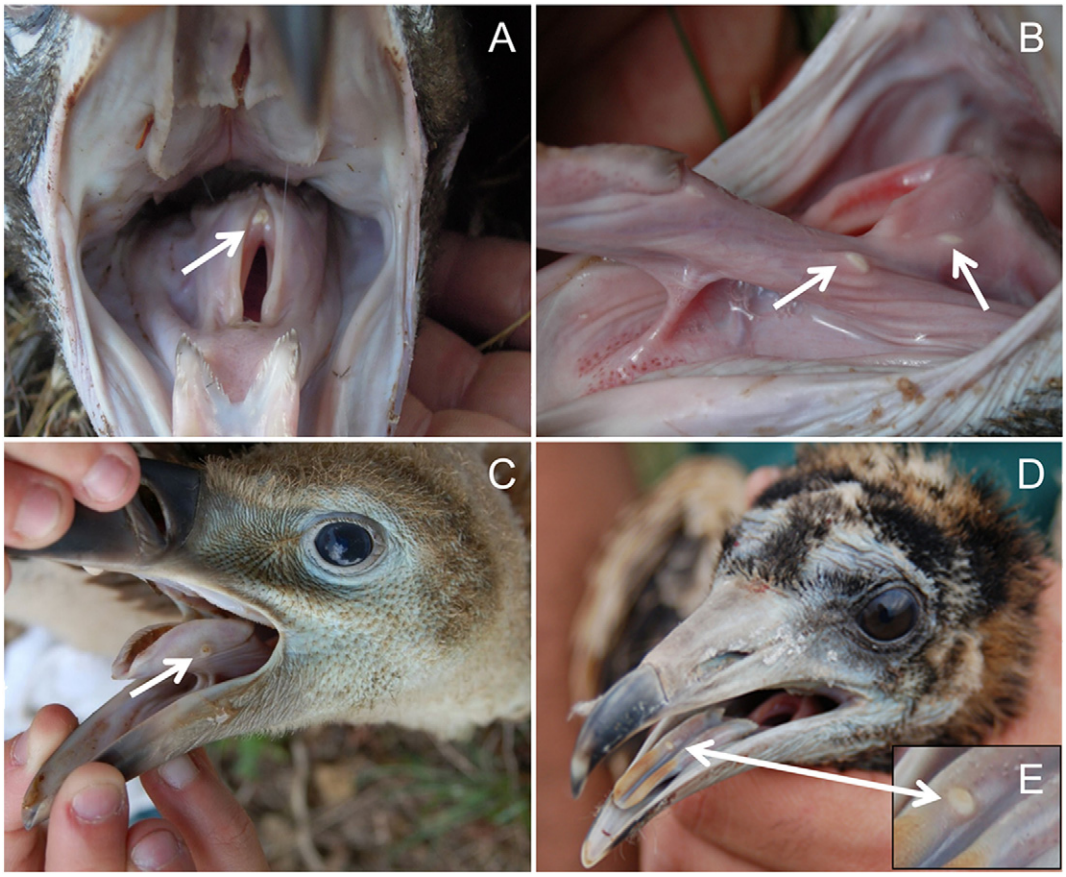

Fig. 1. Examples of lesions caused by yeast-like fungi in the oral cavity of vulture nestlings in central Spain: (A and B) cinereous vulture, (C) griffon vulture and (D and E) Egyptian vulture.

nestling griffon vultures (the host species with the greatest sample size). Many of the yeast species isolated in the griffon vultures (6 out of the 12 species) were not found in the cinereous vultures. The yeast species that were most often isolated from oral lesions in more individuals were *Yarrowia lipolytica* in the cinereous vultures (3 out of the 6 nestlings; 50%) and *Candida albicans* in the griffon vultures (5 out of the 16 nestlings; 31%).

In addition to the yeast species identified in oral lesions from the nestling cinereous and griffon vultures, we also isolated two yeast species from lesions in one nestling Egyptian vulture, and a single species from the lesions in one nestling golden eagle (Table 1). Overall, yeasts were isolated from all samples collected from lesions from the four raptor species (prevalence = 100%, $n = 24$).

3.3. Number of yeast species and associations with individual host features

The median number of isolated yeast species per individual did not differ significantly between the nestling cinereous and griffon vultures (cinereous vs. griffon vultures: median, 1.0 vs. 1.5; range, 1–3 vs. 1–4; Mann-Whitney test, $P = 0.7$; Table 1). The isolation of *Y. lipolytica* or *Cryptococcus albidus* from oral lesions of the nestling griffon vultures was significantly associated with those who had smaller or larger tail feather sizes, respectively (Mann-Whitney test, $P = 0.03$, Fig. 3A; Mann-Whitney test, $P = 0.04$, Fig. 3B). Furthermore, the median number of fault bars in the tail feathers of the nestling griffon vultures (controlling for tail feather size due to nestling age) was higher in those that had *Candida zeylanoides* in their oral lesions than in those that did not (median, 7 vs. 0; range, 4–10 vs. 0–3; Mann-Whitney test, $P = 0.007$; Fig. 3C). No significant associations were observed between the other identified yeast species and baseline characteristics, such as sex, weight, wing and tail feather length, or number of fault bars in the tail feathers of the different study species.

4. Discussion

This study indicates that a large proportion of nestling cinereous and griffon vultures in central Spain shows gross thrush-like lesions in the oral cavity. These were previously attributed to yeast-like fungal infections (López-Rull et al., 2015; Blanco et al., 2017a). Here, we isolated and identified a diverse array of yeast species forming part of the lesions in all affected individuals. Direct observation by microscope of samples of the material forming the lesions showed abundant yeast cells (blastospores) and hyphae (Blanco et al., 2017a). Non-yeast fungi were also isolated (but not identified to the species level) from the lesions, although not in all individuals with lesions. These fungi, and probably also bacteria, could opportunistically contribute as concurrent disease agents to exacerbate the impact of the lesions on host health.

The high occurrence of lesions in vultures from central Spain has been previously associated with the chronic exposure to antibiotics from the consumption of medicated livestock carcasses (Blanco et al., 2016, 2017a, 2017b). These pharmaceuticals may alter the host's normal microbiota composition, and facilitate the overgrowth of opportunistic yeasts able to cause disease (Lin et al., 2005; Pfaller and Diekema, 2007; Keeney et al., 2014). There was a greater occurrence of fluoroquinolones, mostly enrofloxacin but also ciprofloxacin (the metabolite of enrofloxacin) and marbofloxacin, reported in the cinereous (100%, $n = 14$) and griffon (92%, $n = 25$) vultures. This agrees with the higher occurrence of oral lesions in these species compared to the Egyptian vultures, which showed a lower occurrence of fluoroquinolones in plasma (44%, $n = 16$) (Blanco et al., 2016, 2017a). The lower incidence of clinical mycoses observed in the Egyptian vultures could thus be

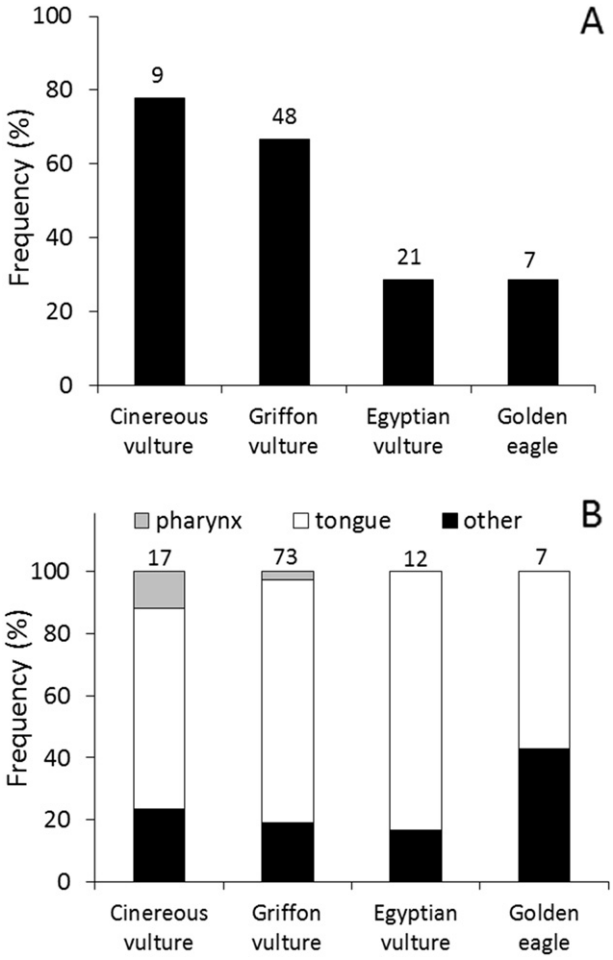

Fig. 2. Frequency of (A) nestlings with yeast-like fungal lesions in the oral cavity, and (B) lesions in each category of location in the four sampled scavenger species. Sample sizes are shown above the bars.

ascribed to a lower food-borne exposure to livestock antibiotics owing to the higher dependence of this species on carcasses of wild rather than domestic animals (Donázar, 1993; Blanco et al., 2017a). In addition, we found for first time the same kind of lesions in the oral cavity of nestling golden eagles, in a proportion of individuals similar to that found in the Egyptian vultures. Pending future validation studies with a greater sample size, the lesions in the golden eagles could also be promoted by exposure to antibiotics from livestock carcasses (71%, $n = 7$; Blanco et al., 2017b). To the best of our knowledge, this is the first study showing a mycosis outbreak caused by a diverse group of yeast species in wild populations of avian scavengers. This unprecedented oral mycosis outbreak in wild avian scavengers is alarming because of the delicate conservation status of several of the affected species, especially the cinereous vulture which showed the highest occurrence of lesions, and the critically endangered Egyptian vulture (BirdLife International, 2016).

The oral lesions ranged from moderate (apparently confined to single small lesions) to severe (when invading the oral cavity). Most of the lesions were located on the tongue and less frequently on the palate and walls of the oral cavity in the four host species. Infection in the pharynx was only recorded in the cinereous and griffon vultures, probably due to the low number of affected individuals of the other two species. The presence of thrush-like lesions was confirmed in fledglings several weeks after leaving the nests. These fledglings were generally reluctant to feed themselves in rehabilitation centers, apparently due to pain during food ingestion, but recovered after treatment with antifungals such as fluconazole and nystatin (P. Prieto, pers. comm., Recovery Center of Wild Animals, Comunidad de Madrid). The observed lesions could be the tip of the iceberg of these mycoses in the affected nestlings, as they may reflect potentially infected lower areas of the digestive tract, which would remain hidden to the observer in live individuals (Friend and Franson, 1999; Deem, 2003). This possibility was confirmed by the generalized presence of the same kind of lesions in the digestive tract (esophagus and crop) recorded during the necropsy of griffon and cinereous vultures conducted in wildlife rehabilitation centers in central Spain (P. Prieto and M. García-Montijano, pers. com., Recovery Center of Wild Animals, Comunidad de Madrid, and authors' own observations). Most affected wild vultures admitted to rehabilitation centers are fledglings during their independence stage. In this stage, both the direct and indirect negative effects of disease and antibiotics can result in long-lasting detrimental consequences on health and survival of affected individuals (Friend and Franson, 1999; Deem, 2003), especially in developing nestlings with an immature immune system (Blanco et al., 2004; López-Rull et al., 2015). These opportunistic mycoses could therefore have a major impact on populations because they may promote fledgling emaciation and dehydration caused by pain during food swallowing, subsequent difficulty with eating and eventual death by starvation (Friend and Franson, 1999; Deem, 2003). In addition, these mycoses can be life-threatening if they become invasive (e.g. candidemia and deep-seat candidiasis) (Pfaller and Diekema, 2007; Shrubsole-Cockwill et al., 2010). Fungal infections during the nestling stage may have adverse effects even in individuals overcoming the disease, as environmental conditions experienced during development can have critical consequences for long-term fitness (Lindström, 1999).

Fourteen yeast species from seven genera (*Candida*, *Meyerozyma*, *Pichia*, *Yarrowia*, *Cryptococcus*, *Rhodotorula* and *Trichosporon*) and two phyla (Ascomycota and Basidiomycota) of the fungal kingdom were isolated from lesions in the oral cavity of the four sampled scavenger species. Although most identified yeast species are known commensal members of the oral and gastrointestinal microbiota of wild birds (Cafarchia et al., 2006; Rippon et al., 2010; Brilhante et al., 2012) and causative pathogens of opportunistic mycoses in humans and domestic animals (Pfaller and Diekema, 2007; Arendrup et al., 2011; Wu et al., 2012), infections with these yeast species in wild birds other than those housed in captivity have rarely been reported (Friend and Franson, 1999; Velasco, 2000; Deem, 2003; Brilhante et al., 2012). Several of the yeast species isolated from the oral lesions were previously identified in griffon vultures admitted in a wildlife rehabilitation center in central Spain, albeit at a lower prevalence and without apparent lesions (García et al., 2007). Remarkably, a recent work reported a case of a poxvirus infection with subsequent secondary systemic dissemination of *C. albicans* and other opportunistic pathogens in a juvenile wild golden eagle (Shrubsole-Cockwill et al., 2010). In our sampling, *T. inkin* was isolated exclusively in the cinereous vultures, while most of the identified yeast species were isolated in the griffon vultures, probably due to a larger sample size of this species. The two yeast species isolated from the lesions of the single nestling Egyptian vulture were also identified in lesions from the other vulture species, while *R. minuta* was only isolated from lesions from the single nestling golden eagle sampled. This suggests that the sample size in this study could be insufficient to detect a proportion of the yeast species present in the avian scavenger populations, especially in those species with a smaller number of sampled individuals.

We found an association between *Y. lipolytica* or *C. albidus* isolation from oral lesions and tail feather size of younger and older nestling griffon vultures, respectively. This finding suggests that the infections caused by particular yeast species may rely on the development stage of the nestlings. This is in accordance with several epidemiological studies reporting the predominant isolation of different *Candida* spp. (*Candida parapsilosis* or *Candida glabrata*) in distinct age groups of candidiasis patients (neonates or the elderly, respectively) (Pfaller and Diekema, 2007; Puig-Asensio et al., 2014). Our data also uncovered a higher number of fault bars (as a proxy of stressful conditions during

Table 1
Distribution of the different yeast species isolated from lesions in the oral cavity in nestlings of the four wild avian scavenger species examined in central Spain.

Yeast species ($n = 14$)	Host species				All host individuals ($n = 24$)	All yeast isolates ($n = 41$)
	Cinereous vulture ($n = 6$)	Griffon vulture ($n = 16$)	Egyptian vulture[a] ($n = 1$)	Golden eagle[a] ($n = 1$)		
Number (%) of yeast isolates						
Ascomycota						
Candida spp.						
Candida albicans	2 (33.3)	5 (31.3)			7 (29.2)	7 (17.1)
Candida famata	1 (16.7)	1 (6.3)			2 (8.3)	2 (4.9)
Candida parapsilosis	1 (16.7)	2 (12.5)			3 (12.5)	3 (7.3)
Candida rugosa		2 (12.5)			2 (8.3)	2 (4.9)
Candida tropicalis		2 (12.5)			2 (8.3)	2 (4.9)
Candida zeylanoides		4 (25.0)			4 (16.7)	4 (9.8)
Meyerozyma spp.						
Meyerozyma guilliermondii (Candida guilliermondii)		1 (6.3)			1 (4.2)	1 (2.4)
Pichia spp.						
Pichia fermentans (Candida lambica)	1 (16.7)	2 (12.5)	+		4 (16.7)	4 (9.8)
Yarrowia spp.						
Yarrowia lipolytica (Candida lipolytica)	3 (50.0)	3 (18.8)			6 (25.0)	6 (14.6)
Basidiomycota						
Cryptococcus spp.						
Cryptococcus albidus	1 (16.7)	4 (25.0)			5 (20.8)	5 (12.2)
Rhodotorula spp.						
Rhodotorula glutinis		1 (6.3)			1 (4.2)	1 (2.4)
Rhodotorula mucilaginosa		1 (6.3)	+		2 (8.3)	2 (4.9)
Rhodotorula minuta				+	1 (4.2)	1 (2.4)
Trichosporon spp.						
Trichosporon inkin	1 (16.7)				1 (4.2)	1 (2.4)
Yeast species/bird ratio (total numbers)	1.7 (10/6)	1.8 (28/16)	2.0 (2/1)	1.0 (1/1)	1.7 (41/24)	
Median number (range) of yeast species per individual	1 (1–3)	1.5 (1–4)	2	1	1 (1–4)	
Number (%) of individuals with yeast-like fungi	6 (100.0)	16 (100.0)	1	1	24 (100.0)	
Number (%) of individuals with non-yeast fungi[b]	4 (66.7)	13 (81.2)	1	1	19 (79.2)	

+ Indicates the isolation of these yeast species.
[a] Percentages and ranges are not shown because of the sample size of this group ($n = 1$).
[b] Non-yeast fungi comprise filamentous fungi.

development) when *C. zeylanoides* was isolated from oral lesions in the nestling griffon vultures than when it was not. Interestingly, these two results could be related. An early infection with *Y. lipolytica* may promote a detrimental growth stress (reflected in a high number of fault bars), which could increase with later infections caused by *C. zeylanoides* during subsequent development stages. Taken together, these findings suggest differential infections and effects depending on host age-related exposure or susceptibility to different yeast species across the development of the immune system (López-Rull et al., 2015). Further research with a larger sample size will contribute to properly identifying the impact of infection by each particular yeast species or combination of species depending on the age and other factors of developing nestlings.

To our knowledge, this is the first report of an isolation of multiple yeast species from oral lesions of wild avian scavengers. However, this study was not designed to completely assess the yeast community that may potentially be present in the oral lesions. Rather, we aimed to confirm that several yeast species can act as disease agents when these turn from commensals to opportunistic pathogens due to the disruption of a host's biological homeostasis and resistance (Hebecker et al., 2014), from chronic and chaotic host exposure to broad-spectrum antibiotics. The combination of microbiological cultivation with molecular methods could aid in identifying other yeast species potentially present as commensals and pathogens contributing to the lesions. Such methods include genotypic tools, phylogenetic investigation and analysis based on enzymatic digestion of some genes, among others. This is especially true for species-specific yeasts that are not included in the commercial kits, like the API 20 AUX system, as this was mainly designed to identify human pathogens. It is also worth mentioning that non-yeast-like fungi were also isolated in several lesions. Given that these filamentous fungi might contribute to disease pathogenesis (Mukherjee et al., 2015), future studies should be aimed at characterizing these non-yeast-like fungi. This will contribute further insight into microbial co-occurrence relationships during infection as well as the functionality of the microbial ecosystem in wild populations, both in health and in disease.

Importantly, exposure of avian scavengers to livestock antibiotics and yeasts may simultaneously occur from livestock carcasses in the unsanitary conditions encountered in feeding stations, which are paradoxically aimed at the conservation of these species (Cortés-Avizanda et al., 2016). In view of our findings, further research is now warranted to shed new light on the relationships between the unintended exposure to livestock antibiotics and development of fungal infections in wild avian scavengers. Whether both factors act together to threaten these populations, particularly those of the critically endangered Egyptian vulture should be assessed. Since many of the isolated yeasts are considered new emerging pathogens (Fisher et al., 2012), further research should focus on the impact of these yeast species and host-pathogen interactions. The role of livestock antibiotics in the transition of yeast species from commensal to opportunistic pathogens should be evaluated in an attempt to avoid the detrimental effects of contamination and disease on host health, as well as on the transmission of fungal emerging pathogens among wildlife populations and species, and their dissemination across livestock and human populations.

Acknowledgments

We thank Ó. Frías, J.L. González, F. Martínez, J.M. García and B. Arroyo for their help with fieldwork. We are also indebted to C. Pintado, C. Rodríguez and M.C. de la Rosa for their excellent technical assistance in the identification of yeast species. Funds were provided by the projects CGL2009-12753-C02-01/BOS and CGL2010-15726 of the Ministry

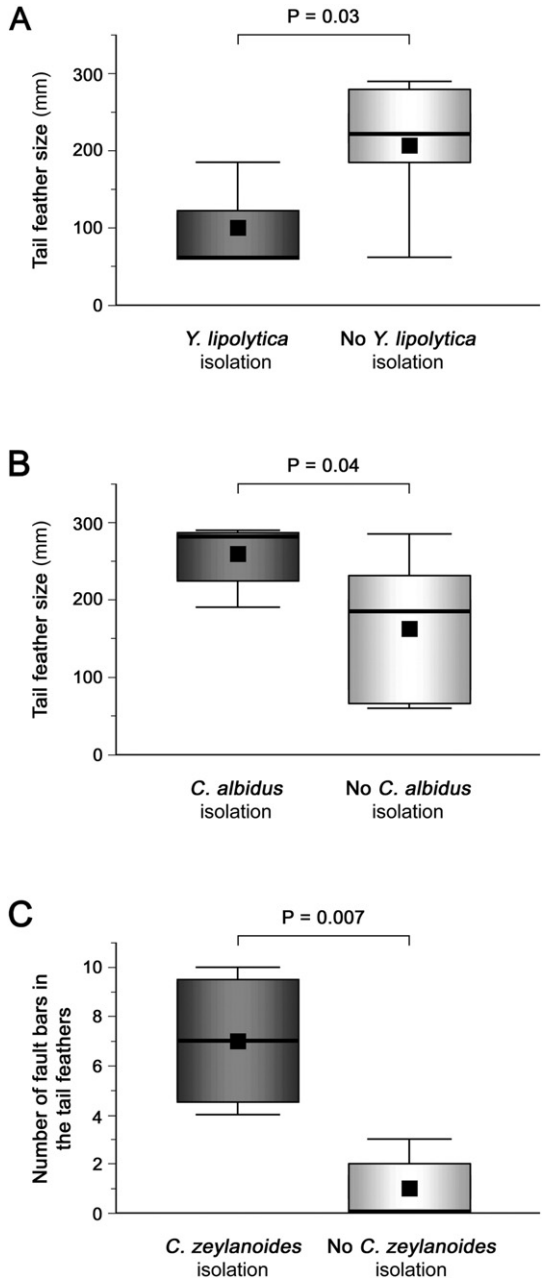

Fig. 3. Distribution of (A and B) the tail feather size and (C) number of fault bars in the tail feathers of nestling griffon vultures according to the isolation of (A) *Y. lipolytica*, (B) *C. albidus* and (C) *C. zeylanoides* from their oral lesions. The *boxes* depict the interquartile ranges (25th to 75th percentiles), the *horizontal thick lines* represent the medians, the *black squares* show the means, and the *whiskers* extend to 1.5 times the interquartile range.

of Economy and Competitiveness, Spain. We acknowledge the efforts of two anonymous reviewers in improving the paper's content.

Appendix A. Supplementary data

Supplementary data to this article can be found online at http://dx.doi.org/10.1016/j.scitotenv.2017.06.144.

References

Arendrup, M.C., Bruun, B., Christensen, J.J., Fuursted, K., Johansen, H.K., Kjaeldgaard, P., Knudsen, J.D., Kristensen, L., Møller, J., Nielsen, L., Rosenvinge, F.S., Røder, B., Schønheyder, H.C., Thomsen, M.K., Truberg, K., 2011. National surveillance of fungemia in Denmark (2004 to 2009). J. Clin. Microbiol. 49, 325–334.

Arnold, K.E., Brown, A.R., Ankley, G.T., Sumpter, J.P., 2014. Medicating the environment: assessing risks of pharmaceuticals to wildlife and ecosystems. Philos. Trans. R. Soc. B 369, 20130569.

BirdLife International, 2016. IUCN red list for birds. Downloaded from. http://www.birdlife.org (on 28/06/2016).

Blanco, G., 2014. Can livestock carrion availability influence diet of wintering red kites? Implications of sanitary policies in ecosystem services and conservation. Popul. Ecol. 56, 593–604.

Blanco, G., 2015. Multiresistant *Salmonella* serovar typhimurium monophasic in wintering red kites *Milvus milvus* in Segovia, central Spain. J. Raptor Res. 49, 339–341.

Blanco, G., Jiménez, B., Frías, O., Millán, J., Dávila, J.A., 2004. Contamination with nonessential metals from a solid-waste incinerator correlates with nutritional and immunological stress in prefledgling black kites (*Milvus migrans*). Environ. Res. 94, 94–101.

Blanco, G., Junza, A., Segarra, D., Barbosa, J., Barrón, D., 2016. Wildlife contamination with fluoroquinolones from livestock: widespread occurrence of enrofloxacin and marbofloxacin in vultures. Chemosphere 144, 1536–1543.

Blanco, G., Junza, A., Barrón, D., 2017a. Food safety in scavenger conservation: diet-associated exposure to livestock pharmaceuticals and opportunist mycoses in threatened Cinereous and Egyptian vultures. Ecotoxicol. Environ. Saf. 135, 292–301.

Blanco, G., Junza, A., Barrón, D., 2017b. Occurrence of veterinary pharmaceuticals in golden eagle nestlings: unnoticed scavenging on livestock carcasses and other potential exposure routes. Sci. Total Environ. 586, 355–361.

Blanco, G., Cardells, J., Garijo-Toledo, M.M., 2017c. Supplementary feeding and endoparasites in threatened avian scavengers: coprologic evidence from red kites in their wintering stronghold. Environ. Res. 155, 22–30.

Brilhante, R.S., Castelo-Branco, D.S., Duarte, G.P., Paiva, M.A., Teixeira, C.E., Zeferino, J.P., Monteiro, A.J., Cordeiro, R.A., Sidrim, J.J., Rocha, M.F., 2012. Yeast microbiota of raptors: a possible tool for environmental monitoring. Environ. Microbiol. Rep. 4, 189–193.

Cabañes, F.J., 2010. Yeast pathogens of domestic animals. In: Ashbee, H.R., Bignell, E.M. (Eds.), Pathogenic Yeasts. Springer, Berlin Heidelberg, pp. 253–279.

Cafarchia, C., Romito, D., Iatta, R., Camarda, A., Montagna, M.T., Otranto, D., 2006. Role of birds of prey as carriers and spreaders of *Cryptococcus neoformans* and other zoonotic yeasts. Med. Mycol. 44, 485–492.

Caliendo, V., Bull, A., 2011. Ventricular candidiasis in stone curlews (*Burhinus oedicnemus*). Avian Dis. 55, 509–512.

Carter, T.A., Nancy, J.T., Hunter, D.B., 2008. Parasitic Diseases of Wild Birds. Wiley-Blackwell, Singapore.

Cortés-Avizanda, A., Blanco, G., DeVault, T.L., Markandya, A., Virani, M.Z., Donázar, J.A., 2016. Supplementary feeding and endangered avian scavengers: benefits, caveats and controversies. Front. Ecol. Environ. 14:191–199. http://dx.doi.org/10.1002/fee.1257.

Cunha, B.A., 2001. Antibiotic side effects. America]–>Med. Clin. N. Am. 85, 149–185.

Deem, S.L., 2003. Fungal diseases of birds of prey. Vet. Clin. North Am. Exot. Anim. Pract. 6, 363–376.

Donázar, J.A., 1993. Los buitres ibéricos. J.M. Reyero, Madrid.

Donázar, J.A., Blanco, G., Hiraldo, F., Soto-Largo, E., Oria, J., 2002. Effects of forestry and other land-use practices on the conservation of cinereous vultures. Ecol. Appl. 12, 1445–1456.

Farah, C.S., Lynch, N., McCullough, M.J., 2010. Oral fungal infections: an update for the general practitioner. Australian Dental Journal]–>Aust. Dent. J. 55, 48–54.

Fargallo, J.A., Blanco, G., Soto-Largo, E., 1998. Forest management effects on nesting habitat selected by Eurasian Black Vultures *Aegypius monachus* in central Spain. J. Raptor Res. 32, 202–207.

Feng, L., Wan, Z., Wang, X., Li, R., Liu, W., 2010. Relationship between antifungal resistance of fluconazole resistant *Candida albicans* and mutations in ERG11 gene. Chin. Med. J. 123, 544–548.

Fisher, M.C., Henk, D.A., Briggs, C.J., Brownstein, J.S., Madoff, L.C., McCraw, S.L., Gurr, S.J., 2012. Emerging fungal threats to animal, plant and ecosystem health. Nature 484, 186–194.

Friend, M., Franson, J.C., 1999. Field Manual of Wildlife Diseases General Field Procedures and Disease of Birds/Biological Resources Division Information and Technology Report 1999–001. US Department of Interior United States Geological Sciences, Washington, DC.

García, M.E., Lanzarot, P., Rodas, V.L., Costas, E., Blanco, J.L., 2007. Fungal flora in the trachea of birds from a wildlife rehabilitation centre in Spain. Vet. Med. 52, 467–470.

Hebecker, B., Naglik, J.R., Hube, B., Jacobsen, I.D., 2014. Pathogenicity mechanisms and host response during oral *Candida albicans* infections. Expert Rev. Anti-Infect. Ther. 12, 867–879.

Keeney, K.M., Yurist-Doutsch, S., Arrieta, M.C., Finlay, B.B., 2014. Effects of antibiotics on human microbiota and subsequent disease. Annu. Rev. Microbiol. 68, 217–235.

Lalla, R.V., Patton, L.L., Dongari-Bagtzoglou, A., 2013. Oral candidiasis: pathogenesis, clinical presentation, diagnosis and treatment strategies. J. Calif. Dent. Assoc. 41, 263–268.

Levy, J., 2000. The effects of antibiotic use on gastrointestinal function. American Journal of Gastroenterology]–>Am. J. Gastroenterol. 95, S8–10.

Lin, M.Y., Carmeli, Y., Zumsteg, J., Flores, E.L., Tolentino, J., Sreeramoju, P., Weber, S.G., 2005. Prior antimicrobial therapy and risk for hospital-acquired *Candida glabrata* and *Candida krusei* fungemia: a case-case-control study. Antimicrob. Agents Chemother. 49, 4555–4560.

Lindström, J., 1999. Early development and fitness in birds and mammals. Trends Ecol. Evol. 14, 343–348.

López-Rull, I., Hornero-Mendez, D., Frías, O., Blanco, G., 2015. Age-related relationships between innate immunity and plasma carotenoids in an obligate avian scavenger. PLoS ONE 10, e0141759. http://dx.doi.org/10.1371/journal.pone.0141759.

MacCallum, D.M., 2010. *Candida infections* and modelling disease. In: Ashbee, H.R., Bignell, E.M. (Eds.), Pathogenic Yeasts. Springer, Berlin, pp. 41–67.

Mancianti, F., Nardoni, S., Ceccherelli, R., 2002. Occurrence of yeasts in psittacines droppings from captive birds in Italy. Mycopathologia 153, 121–124.
Martínez, F., Rodríguez, R.F., Blanco, G., 1997. Effects of monitoring frequency on estimates of abundance, age distribution, and productivity of colonial Griffon Vultures. J. Field Ornithol. 68, 392–399.
Meissner, W., Dynowska, M., Góralska, K., Rzyska, H., 2015. Mallards (*Anas platyrhynchos*) staying in urban environments have higher levels of microfungi biota diversity than do birds from non-urban areas. Fungal Ecol. 17, 164–169.
Mukherjee, P.K., Sendid, B., Hoarau, G., Colombel, J.F., Poulain, D., Ghannoum, M.A., 2015. Mycobiota in gastrointestinal diseases. Nat. Rev. Gastroenterol. Hepatol. 12, 77–87.
Neville, B.A., d'Enfert, C., Bougnoux, M.E., 2015. *Candida albicans* commensalism in the gastrointestinal tract. FEMS Yeast Res. 15, fov081.
Pfaller, M.A., Diekema, D.J., 2007. Epidemiology of invasive candidiasis: a persistent public health problem. Clin. Microbiol. Rev. 20, 133–163.
Pitarch, A., Nombela, C., Gil, C., 2006. *Candida albicans* biology and pathogenicity: insights from proteomics. Methods Biochem. Anal. 49, 285–330.
Prakash, V., Bishwakarma, M.C., Chaudhary, A., Cuthbert, R., Dave, R., Kulkarni, M., Kumar, S., Paudel, K., Ranade, S., Shringarpure, R., Green, R.E., 2012. The population decline of *Gyps* vultures in India and Nepal has slowed since the veterinary use of diclofenac was banned. PLoS ONE 7, e49118.
Puig-Asensio, M., Padilla, B., Garnacho-Montero, J., Zaragoza, O., Aguado, J.M., Zaragoza, R., Montejo, M., Muñoz, P., Ruiz-Camps, I., Cuenca-Estrella, M., Almirante, B., CANDIPOP, Project, GEIH-GEMICOMED (SEIMC), REIPI, 2014. Epidemiology and predictive factors for early and late mortality in Candida bloodstream infections: a population-based surveillance in Spain. Clin. Microbiol. Infect. 20, 245–254.
Ramani, R., Gromadzki, S., Pincus, D.H., Salkin, I.F., Chaturvedi, V., 1998. Efficacy of API 20C and ID 32C systems for identification of common and rare clinical yeast isolates. J. Clin. Microbiol. 36, 3396–3398.
Redig, P., 2003. Fungal diseases. In: Samour, J. (Ed.), Avian Medicine. Elsevier Science, Edinburgh, pp. 275–291.
Rippon, R.J., Alley, M.R., Castro, I., 2010. *Candida albicans* infection in free-living populations of hihi (stitchbird; *Notiomystis cincta*). New Zealand Veterinary Journal]–>N. Z. Vet. J. 58, 299–306.
Sanz-Aguilar, A., Cortés-Avizanda, A., Serrano, D., Blanco, G., Ceballos, O., Grande, J.M., Tella, J.L., Donázar, J.A., 2017. Sex-and age-dependent patterns of survival and breeding success in a long-lived endangered avian scavenger. Sci Rep 7, 40204.
Shrubsole-Cockwill, A.N., Millins, C., Jardine, C., Kachur, K., Parker, D.L., 2010. Avian pox infection with secondary *Candida albicans* encephalitis in a juvenile golden eagle (*Aquila chrysaetos*). J. Avian Med. Surg. 24, 64–71.
Velasco, M.C., 2000. Candidiasis and cryptococcosis in birds. Seminars in Avian and Exotic Pet Medicine. 9, pp. 75–81.
Vieira, R.G., Acqua-Coutinho, S.D., 2009. Phenotypical characterization of *Candida* spp. isolated from crop of parrots (*Amazona* spp.). Pesqui. Vet. Bras. 29, 452–456.
Walker, R.D., 2000. Fluoroquinolones. In: Prescott, J.F., Baggot, J.D., Walker, R.D. (Eds.), Antimicrobial Therapy in Veterinary Medicine, 3rd edition Iowa State University Press, Ames, pp. 315–338.
Wink, M., Sauer-Gürth, H., Martínez, F., Doval, G., Blanco, G., Hatzofe, O., 1998. The use of (GACA) 4-PCR to sex old world vultures (Aves: Accipitridae). Mol. Ecol. 7, 779–782.
Wu, Y., Du, P.C., Li, W.G., Lu, J.X., 2012. Identification and molecular analysis of pathogenic yeasts in droppings of domestic pigeons in Beijing, China. Mycopathologia 174, 203–214.